

## EDITORIAL COMMENT

# Caseous Mitral Annulus Calcification

## A Rare Complication of a Common Disease That Needs Recognition\*



Sarah M. Birkhoelzer, MD, PGCERT MedEd,<sup>a</sup> Ritu Thamman, MD<sup>b</sup>

**C**aseous (Latin, *caseus*, “cheese”) calcification of the mitral annulus (CMAC) is a rare variant of mitral annular calcification (MAC). It appears as a smooth, round, periannular mass with a central echolucent area and a surrounding hyperechogenic rim, which does not show flow or acoustic shadow artifacts. MAC has a J-, C-, or U-shaped dense echocardiographic band, which creates acoustic shadowing but lacks the echolucent center (1). CMAC can be mistaken for vegetation and tumors (2).

The echocardiographic prevalence of CMAC is 0.64% of patients with MAC and 0.068% of the general population (3). The prevalence at autopsy is higher (2.7%) (4), suggesting that this condition is yet under-recognized. It is more common with increased age, female sex (5–7), hypertension, chronic kidney disease (CKD), or altered calcium-phosphate metabolism (8). Although patients with MAC have a twofold increased risk of stroke independent of conventional risk factors (9), it is unknown whether CMAC carries the same risk. The prevalence of MAC is heavily influenced by both the population-studied baseline characteristics (i.e., age, sex, CKD, and imaging modality). In contrast to computed tomography (CT), echocardiography does not distinguish between fibrosis and calcium.

The pathophysiology of MAC is heterogeneous. The structures involved may or may not include the mitral leaflets, chordae, papillary muscles, or left ventricular or atrial wall. The calcific material may be densely compacted, friable, or caseous. The extent of involvement may be localized, patchy, or extensive and involve 1 or multiple structures.

Multiple cases in the medical literature highlight the dynamic link between MAC and CMAC, their characteristic features shown on multimodality imaging and treatment options (Figure 1). Most cases are incidentally found on echocardiograms or during catheterization with fluoroscopy of the annulus. Rarely, patients present with murmurs secondary to cardiac pseudotumor or symptoms of cerebral emboli. Multimodal imaging is the key to differentiate among typical MAC, CMAC, and other cardiac masses such as calcified amorphous tumor, an extremely rare non-neoplastic cardiac tumor (2).

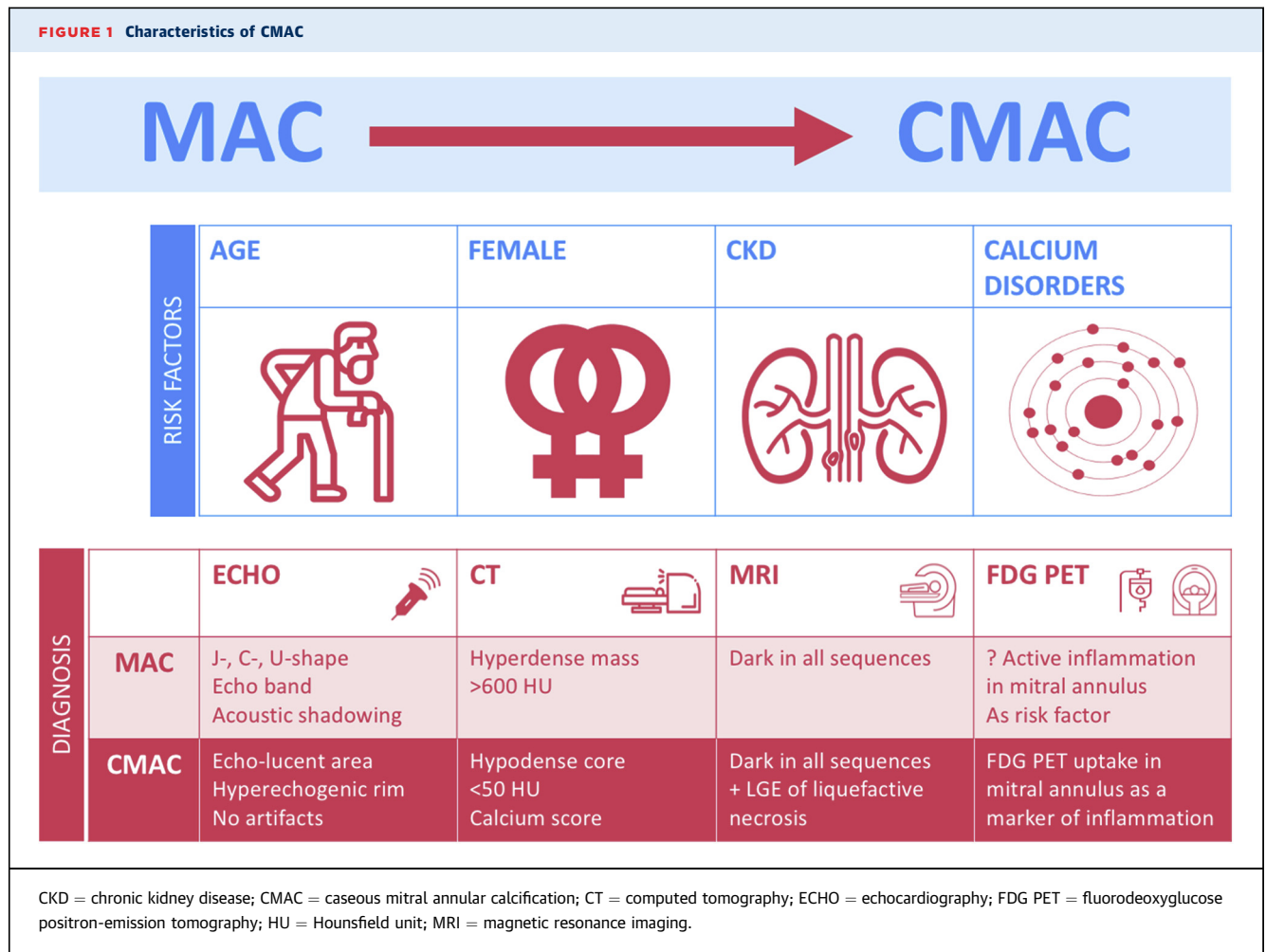
On cardiac magnetic resonance imaging, calcium appears dark in all sequences. CMAC has a low signal on T2-weighted images and a bright signal with a hyperintense center and hypointense rim on T1-weighted images. Fat suppression does not alter signal characteristics. Late gadolinium-enhanced imaging is used to demonstrate the liquefactive necrosis in CMAC (10). As observed on cardiac CT, the progression from MAC to CMAC can be shown by density attenuation (Hounsfield unit [HU]), as MAC is visible as a hyperdense (>600 HU) mass. In contrast, caseous necrosis of CMAC has a low-density core (<50 HU) (11).

In this issue of *JACC: Case Reports*, Mayr et al. (12) highlight the association of CMAC with CKD, embolic risks, and the progression of MAC to CMAC. Their study draws attention to many unresolved questions including which factors lead MAC to degenerate into CMAC, the influence of calcium

\*Editorials published in *JACC: Case Reports* reflect the views of the authors and do not necessarily represent the views of *JACC: Case Reports* or the American College of Cardiology.

From the <sup>a</sup>Department of Cardiology, Portsmouth Hospitals University National Health Service Trust, Portsmouth, United Kingdom; and the <sup>b</sup>Department, University of Pittsburgh School of Medicine, Pittsburgh, Pennsylvania, USA.

The authors attest they are in compliance with human studies committees and animal welfare regulations of the authors' institutions and Food and Drug Administration guidelines, including patient consent where appropriate. For more information, visit the [Author Center](#).

**FIGURE 1** Characteristics of CMAC

burden at MAC presentation, and which role altered calcium metabolism plays. CMAC and MAC offer unfavorable surgical treatment features; however, with the contemporary advances in treating structural heart disease with transcatheter aortic and transcatheter mitral valve replacement, recognizing CMAC is imperative. The cardiologist must be aware of this increasingly recognized entity and facilitate multimodal imaging to assess cardiac masses and discuss them with the multidisciplinary heart valve team.

A MAC severity score has been developed to predict the rate of embolization during transcatheter mitral valve replacement (13). The score may be used to predict the development of CMAC, as baseline MAC severity was identified as the main predictor for future MAC progression (14). The ability to predict progression from MAC to CMAC based on the coronary calcium score should be examined as the MAC burden increases coronary artery calcium score (15).

Positron emission tomography CT can be used to assess the prevalence, disease activity, and progression of MAC. Depending on the tracer choice, calcification activity or degree of inflammation can be assessed alongside CT assessment of valvular anatomy. Fluorine-18-labeled fluorodeoxyglucose uptake in the mitral annulus may correlate with active inflammation in the mitral annulus, the progression to CMAC, and anti-inflammatory treatment approach to reduce progression of MAC to CMAC (16).

The degree and distribution of calcification around the mitral valve annulus seems to be a key factor in the pathophysiology of CMAC and associated with coronary artery calcification. Annular calcification may be a target for therapeutic strategies to halt the progression of MAC. A registry is required to understand risk factors, the consequences of the disease, the evolution from MAC to CMAC, and subsequent timing of potential treatments, including risk factor modification, medical treatment, interventional approach, or surgical management.

This topic becomes more relevant as our population ages and atherosclerotic vascular disease increases. Multimodal imaging is increasingly available and may be used to collect prognostic data and inform appropriate treatment strategies to slow MAC progression. Novel interventional and surgical treatment options are under development and review to treat more complex and advanced mitral valve disease, including CMAC.

## AUTHOR DISCLOSURES

Both authors have reported that they have no relationships relevant to the contents of this paper to disclose.

**ADDRESS FOR CORRESPONDENCE:** Dr. Sarah Birkhoelzer, Portsmouth Hospitals University NHS Trust, Southwick Hill Road, Cosham, Portsmouth PO6 3LY, United Kingdom. E-mail: [Sarah.birkhoelzer@gmail.com](mailto:Sarah.birkhoelzer@gmail.com). Twitter: [@birkhoelzerS](https://twitter.com/birkhoelzerS).

## REFERENCES

1. Akram M, Hasanin AM. Caseous mitral annular calcification: is it a benign condition? *J Saudi Heart Assoc* 2012;24:205–8.
2. Reynolds C, Tazelaar HD, Edwards WD. Calcified amorphous tumor of the heart (cardiac CAT). *Hum Pathol* 1997;28:601–6.
3. Deluca G, Correale M, Ieva R, Del Salvatore B, Gramenzi S, Di Biase M. The incidence and clinical course of caseous calcification of the mitral annulus: a prospective echocardiographic study. *J Am Soc Echocardiogr* 2008;21:828–33.
4. Pomerance A. Pathological and clinical study of calcification of the mitral valve ring. *J Clin Pathol* 1970;23:354–61.
5. O'Neal WT, Efrid JT, Nazarian S, et al. Mitral annular calcification progression and the risk of atrial fibrillation: results from MESA. *Eur Heart J Cardiovasc Imaging* 2018;19:279–84.
6. Kohsaka S, Jin Z, Rundek T, et al. Impact of mitral annular calcification on cardiovascular events in a multiethnic community: the Northern Manhattan Study. *J Am Coll Cardiol Img* 2008;1: 617–23.
7. Fox CS, Vasan RS, Parise H, et al. Mitral annular calcification predicts cardiovascular morbidity and mortality: the Framingham Heart Study. *Circulation* 2003;107:1492–6.
8. Van Hemelrijck M, Taramasso M, Gülmez G, Maisano F, Mestres CA. Mitral annular calcification: challenges and future perspectives. *Indian J Thorac Cardiovasc Surg* 2020;36:397–403.
9. Benjamin EJ, Plehn JF, D'Agostino RB, et al. Mitral annular calcification and the risk of stroke in an elderly cohort. *N Engl J Med* 1992;327:374–9.
10. Di Bella G, Masci PG, Ganame J, Dymarkowski S, Bogaert J. Liquefaction necrosis of mitral annulus calcification: detection and characterization with cardiac magnetic resonance imaging. *Circulation* 2008;117:e292–4.
11. Groves DW, Acharya T, Shanbhag SM, Bandettini WP, Arai AE, Chen MY. Dynamic nature of caseous mitral annular calcification. *J Cardiovasc Comput Tomogr* 2018;12:444.
12. Mayr A, Müller S, Feuchtnner G. The spectrum of caseous mitral annulus calcification. *J Am Coll Case Rep* 2021;3:104–8.
13. Guerrero M, Wang DD, Pursnani A, et al. A cardiac computed tomography-based score to categorize mitral annular calcification severity and predict valve embolization. *J Am Coll Cardiol Img* 2020;13:1945–57.
14. Elmariah S, Budoff MJ, Delaney JA, et al. Risk factors associated with the incidence and progression of mitral annulus calcification: the multi-ethnic study of atherosclerosis. *Am Heart J* 2013; 166:904–12.
15. Hamirani YS, Nasir K, Blumenthal RS, et al. Relation of mitral annular calcium and coronary calcium (from the Multi-Ethnic Study of Atherosclerosis [MESA]). *Am J Cardiol* 2011;107: 1291–4.
16. Massera D, Trivieri MG, Andrews JP, et al. Disease activity in mitral annular calcification: a multimodality study. *Circ Cardiovasc Imaging* 2019;12:e008513.

**KEY WORDS** coronary calcium score, echocardiography, mitral valve